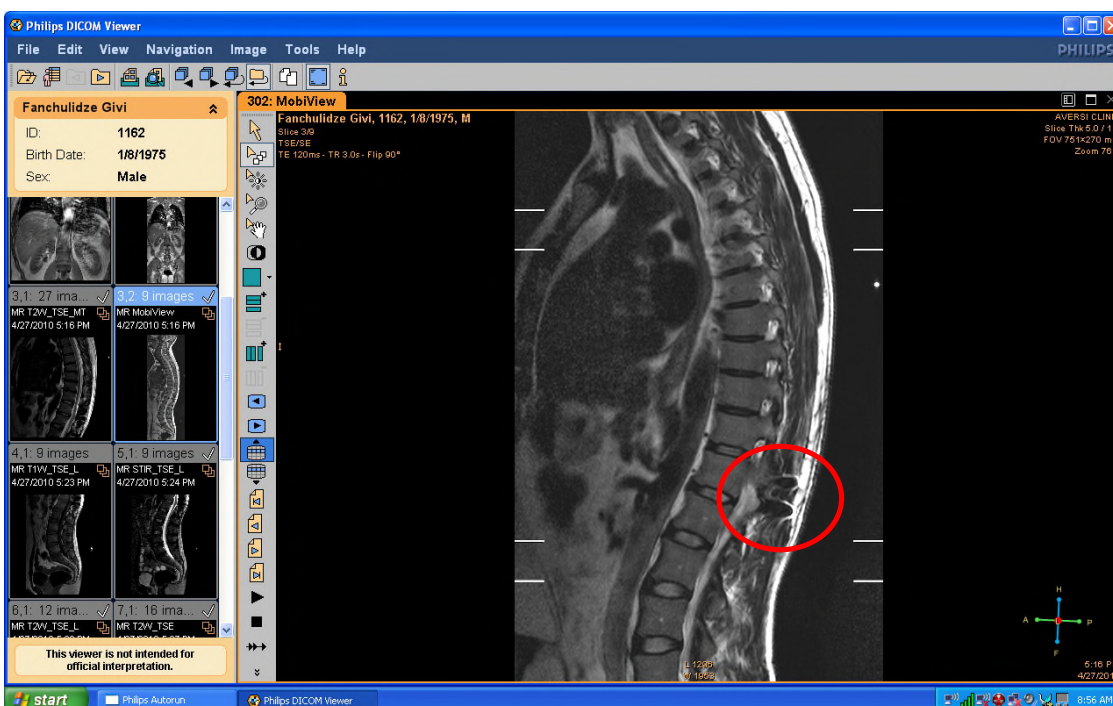


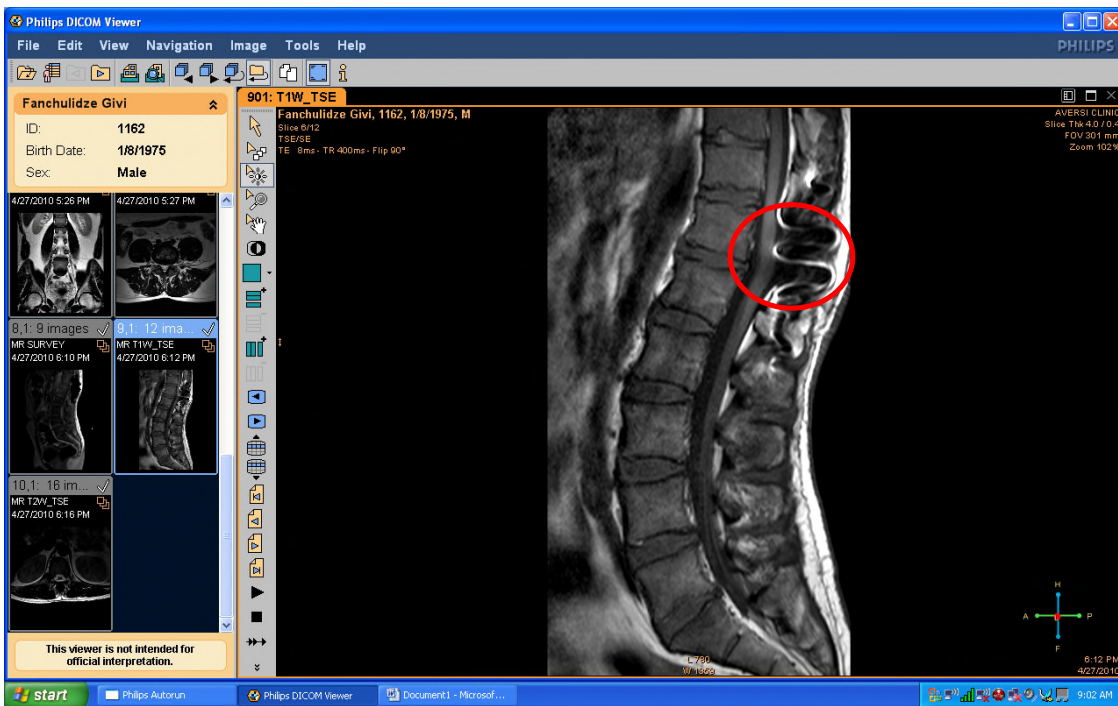
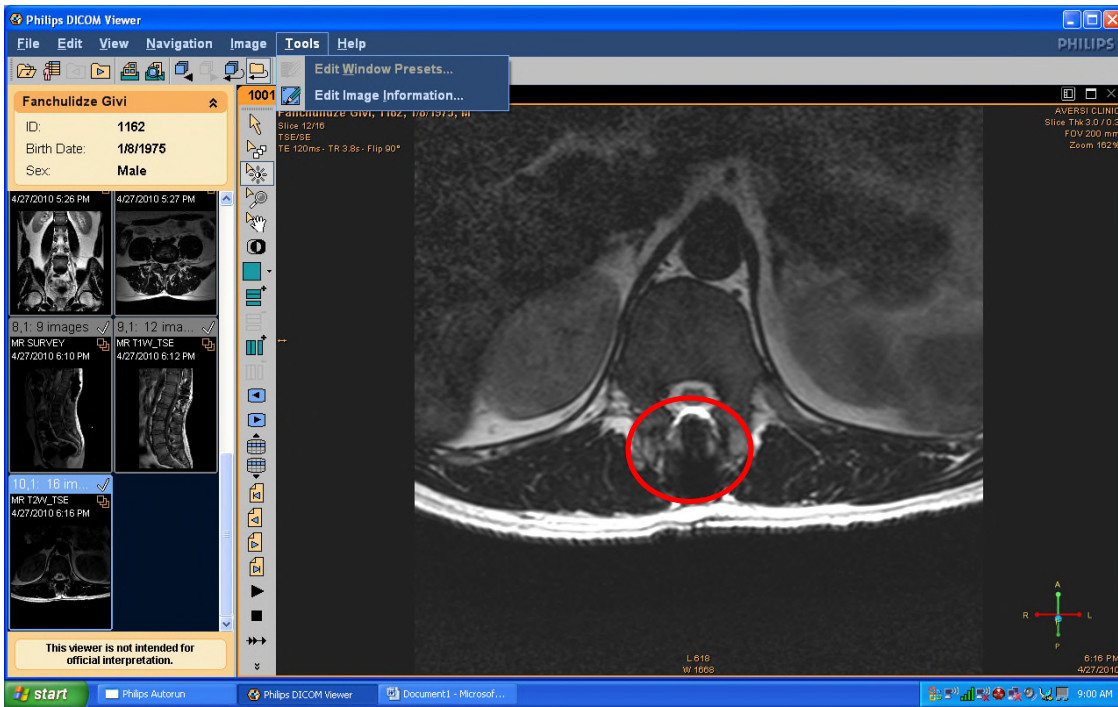
December 14, 2012

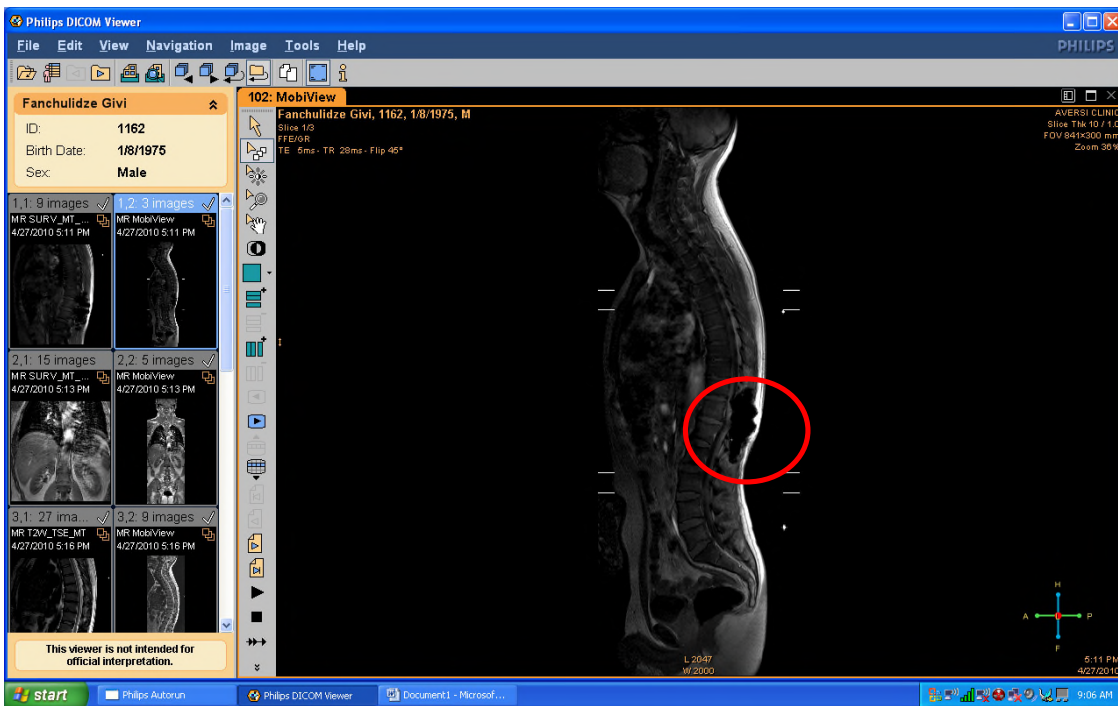
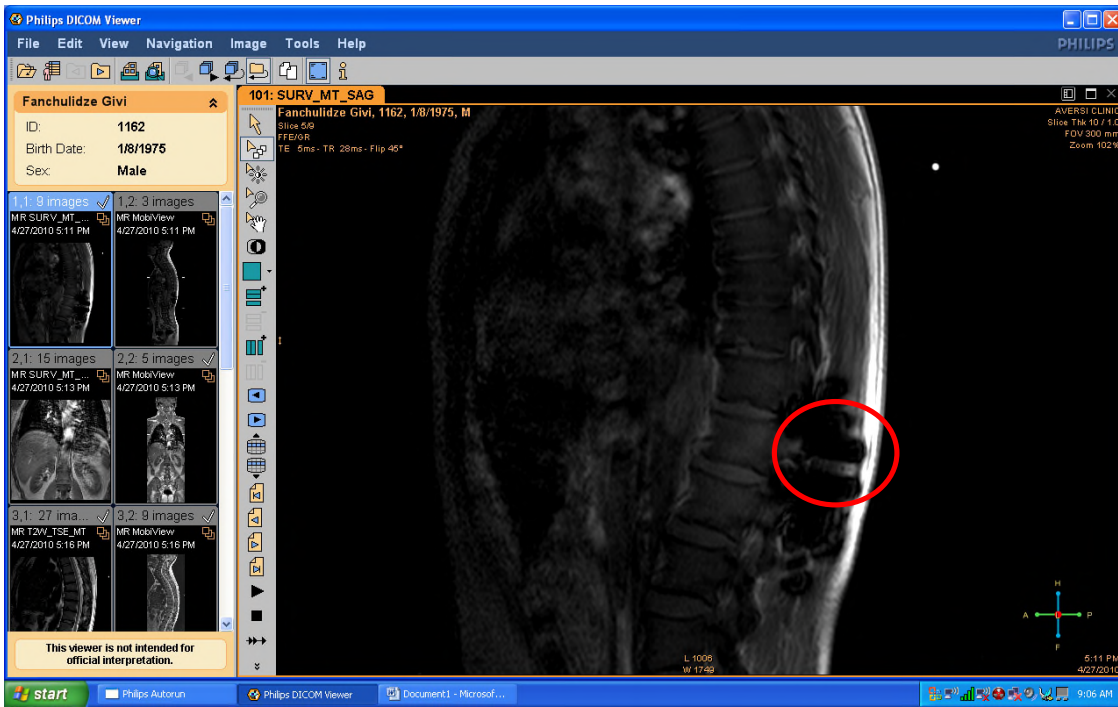
- I was able to get the MRI reviewed using Windows XP operating system, rather than the later Windows 7 operating system, on an older laptop.
- It was difficult to navigate through the CD-ROM software, specifically I was not able to cross correlate axial (horizontal) images with sagittal (lateral vertical) images.
- Nonetheless I was able to make some reasonable interpretations.

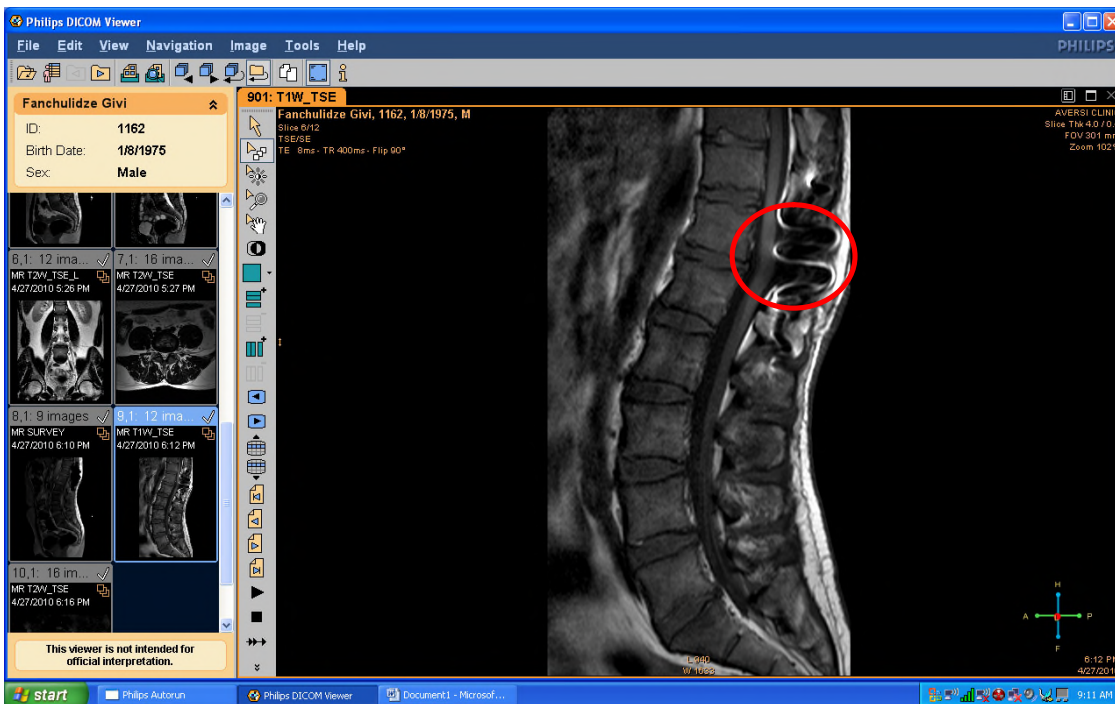
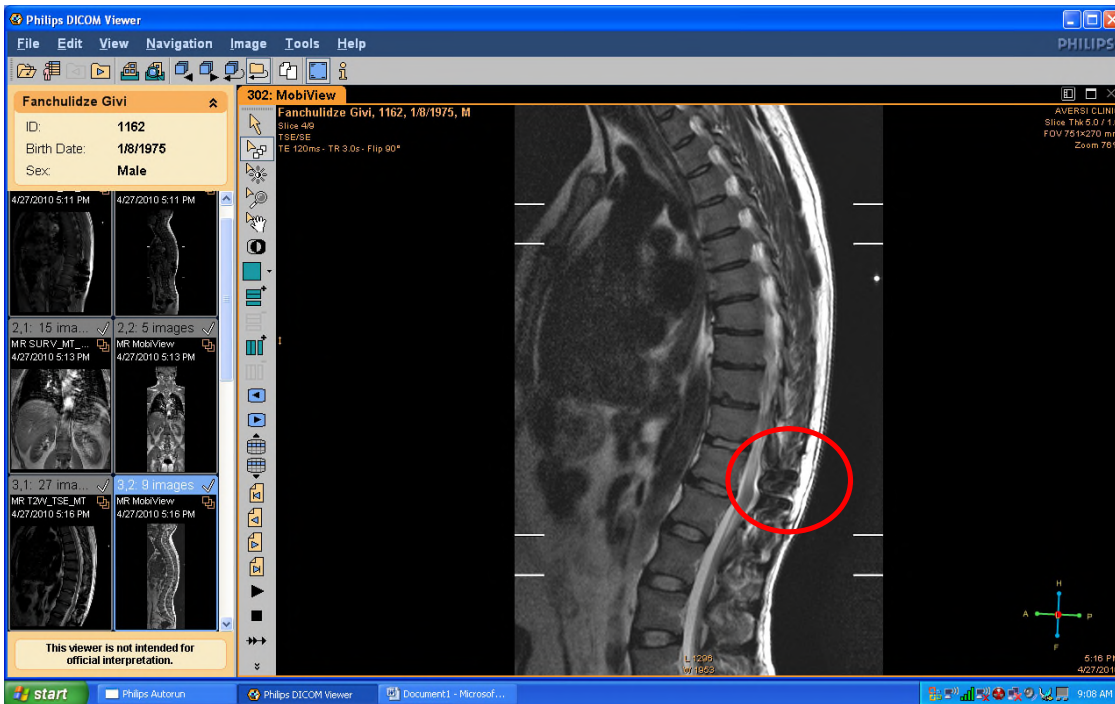
Summary of my findings:

1. **Unusual finding above the lumbar spine, at the junction of the top of the lumbar spine and the bottom of the thoracic spine (bottom of the rib cage):**
 - a. There is a very unusual finding of some type of surgery or prior infection at the junction between the thoracic spine (i.e. bottom of the rib cage) and the top of the lumbar spine. I have never seen this before, and it may be a chronic finding that has nothing to do with the patient's current symptoms.
 - b. I have circled it with a red oval in multiple pictures below.**
 - c. The patient may have had some type of childhood or prior infection or procedure at this level. I simply do not know, and I do not believe it necessarily is a current source of pain.
 - d. One would have to understand where the patient is having pain. **If the patient is having his pain mostly in the lower back, in other words below the waistline, then this is just an incidental, although unusual, imaging finding that does not correlate to his current problem.**
2. **I will assume that his pain is really in the lower back, several inches below this unusual finding at the thoracolumbar junction:**
 - a. If that is the case, I would predict that he does not have significant sciatica.
 - b. He does have some mild disc bulges in the lower lumbar spine, but no evidence of nerve root compression or major disc herniations.
 - c. I do not believe he would benefit for example from a lumbar surgery, again assuming that his pain is really in the lower lumbar area. I cannot say much at all about the unusual finding discussed above.
 - d. **I'm sorry I cannot be more helpful— This is a broad summary of what I have found.**









Richard Seroussi MD, M.Sc.

Diplomate, American Board of PM&R with subspecialty certification in Pain Medicine.

Diplomate, American Board of Electrodiagnostic Medicine.